

Treatment of Facial Photodamage and Rhytides Using a Picosecond Pulsed Alexandrite Laser and Specially Designed Focus Optic.

David H. McDaniel, MD, FAAD

Study Design:

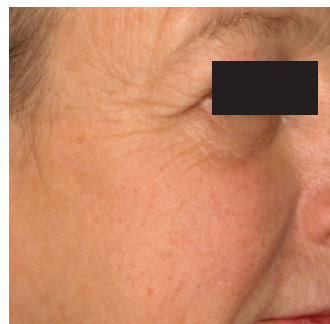
- 20 female subjects.
- 4 full facial treatments at 0.71J/cm², 6.0 mm spot size, 750ps with the focus lens array at one month intervals.
- Post treatment follow-up visits at 1 and 3 months.
- Biopsies were performed on four subjects.

Results:

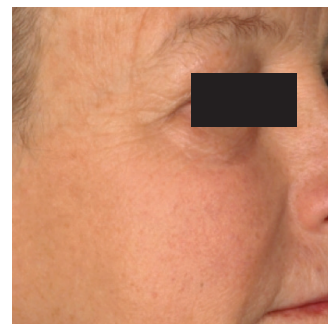
- The treating physician rated that they were "satisfied/extremely satisfied" with approximately 95% of the subject results at both the 1 month and 3 month follow up visits.
- All subjects were improved/very much improved as rated by the treating Physician.
- Average subject response indicated that the subjects were satisfied/extremely satisfied with their results.
- Subjects are likely/extremely likely to refer the treatment to a friend.
- Results from biopsies showed histopathologic evidence of new collagen and elastin.

Conclusion:

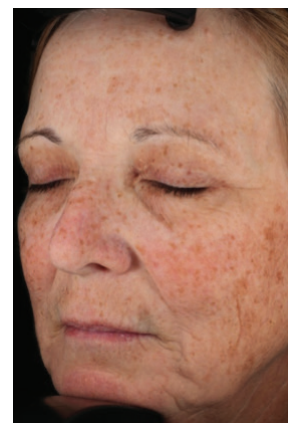- The PicoSure Laser with focus lens array shows significant reduction in pigment dyschromia, global photodamage, erythema and skin radiance and fine lines/wrinkles.
- Visible results can be seen after one treatment.



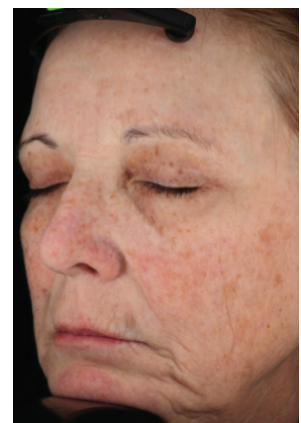Pre-Treatment



Post 2 Treatments



Pre-Treatment



Post 4 Treatments