


Case Study for Port Wine Stain

Prepared by: Maurice A. Adatto, MD

Date: 06/15/2011

Disclaimer: The opinions expressed herein are those of the author(s), not necessarily those of Palomar Medical Technologies, Inc. ("Palomar"). Palomar and the author(s) assume no liability or responsibility for the contents of this publication. It is provided as a convenience only and is not intended to replace sound judgment or serve as the standard of care. Palomar's suggested guidelines are set forth in the operator's manuals and clinical treatment guides for Palomar products. Ultimately, a practitioner is solely responsible for the care of a particular client in light of all circumstances presented by the client, the diagnostic and treatment options at hand, and the available resources.

Profile

Case Study for Port Wine Stain		By: Maurice A. Adatto, MD
Physician name	Maurice A. Adatto, MD	
Address	SKINPULSE Laser Center, 5, Rd-Pt Plainpalais	
City, state, ZIP Code	Geneva, Switzerland, 1205	
Phone number	+4122 807 2777	
Web site address	www.skinpulse.ch	
		
Contact name	Maurice A. Adatto	
Title	Founder & Medical Director	
Phone number	+4122 807 2777	
E-mail address	madatto@skinpulse.ch	

Disclaimer: The opinions expressed herein are those of the author(s), not necessarily those of Palomar Medical Technologies, Inc. ("Palomar"). Palomar and the author(s) assume no liability or responsibility for the contents of this publication. It is provided as a convenience only and is not intended to replace sound judgment or serve as the standard of care. Palomar's suggested guidelines are set forth in the operator's manuals and clinical treatment guides for Palomar products. Ultimately, a practitioner is solely responsible for the care of a particular client in light of all circumstances presented by the client, the diagnostic and treatment options at hand, and the available resources.

Introduction:

33 year-old Caucasian female, Skin Type III, presented with a port wine stain on her left cheek, neck and nape that was untreated since birth.

Discussion:

Planned treatment using the StarLux® 500 with MaxG™ handpiece. I told her she may need at least 4 treatments and should expect about 50% improvement, especially on the cheek area.

Treatment with StarLux® 500 and MaxG™ handpiece:

First treatment :

34 J/cm², 10 ms, one pass, on the cheek

32 J/cm², 10 ms, one pass on the nape

30 J/cm², 10 ms, one pass on the neck area

Second treatment was performed by increasing fluences by 2 J/cm² in each area.

Conclusion:

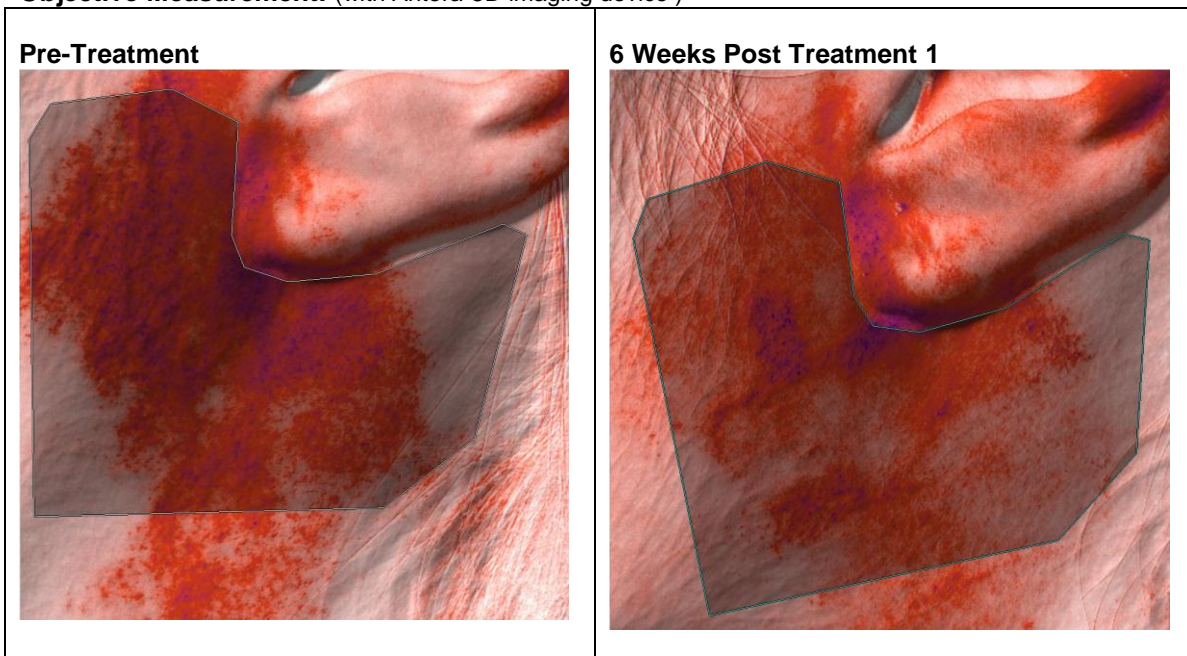
After each session a slight purpuric reaction was visible, which lasted between two and three days. Although it was anticipated that at least 4 treatments would be required, remarkable results were obtained after only 2 treatments. Objective measurements with Antera 3D™ imaging device (Miravex Ltd - Dublin, Ireland) confirms >75% improvement 6 weeks after the second treatment.

Physician Quote: "I believe that StarLux® 500 with MaxG™ handpiece was able to give the best result possible in the fewest sessions possible."

Patient Observation: Patient was waiting for an improvement, but did not expect such a dramatic change in so few sessions. She was extremely pleased.

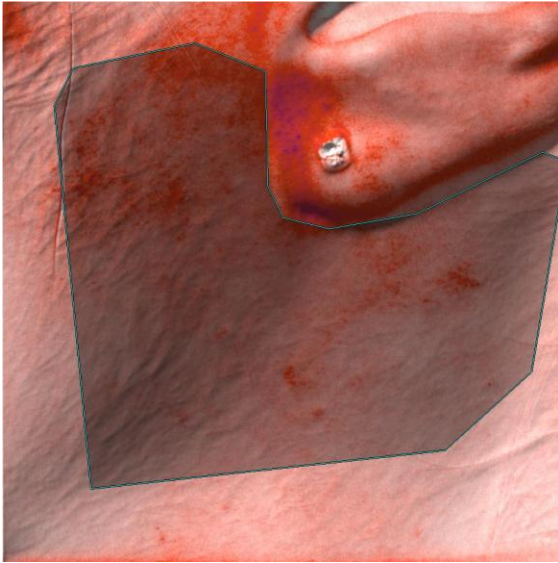
StarLux is a registered trademark and MaxG is a trademark of Palomar Medical Technologies, Inc. (Burlington, MA)
Antera 3D™ is a trademark of Miravex Ltd. (Dublin, Ireland)

Objective Measurement: (with Antera-3D imaging device)

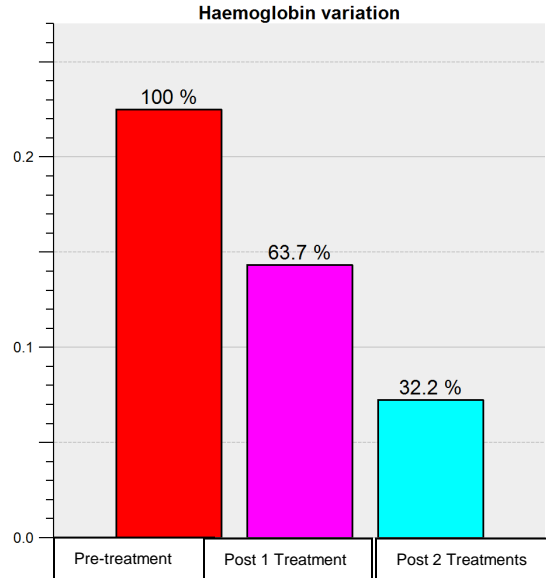


Disclaimer: The opinions expressed herein are those of the author(s), not necessarily those of Palomar Medical Technologies, Inc. ("Palomar"). Palomar and the author(s) assume no liability or responsibility for the contents of this publication. It is provided as a convenience only and is not intended to replace sound judgment or serve as the standard of care. Palomar's suggested guidelines are set forth in the operator's manuals and clinical treatment guides for Palomar products. Ultimately, a practitioner is solely responsible for the care of a particular client in light of all circumstances presented by the client, the diagnostic and treatment options at hand, and the available resources.

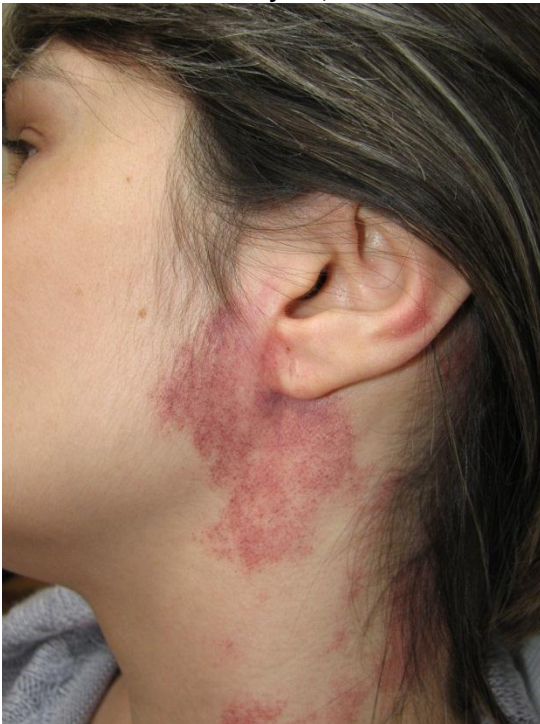6 Weeks Post Treatment 2



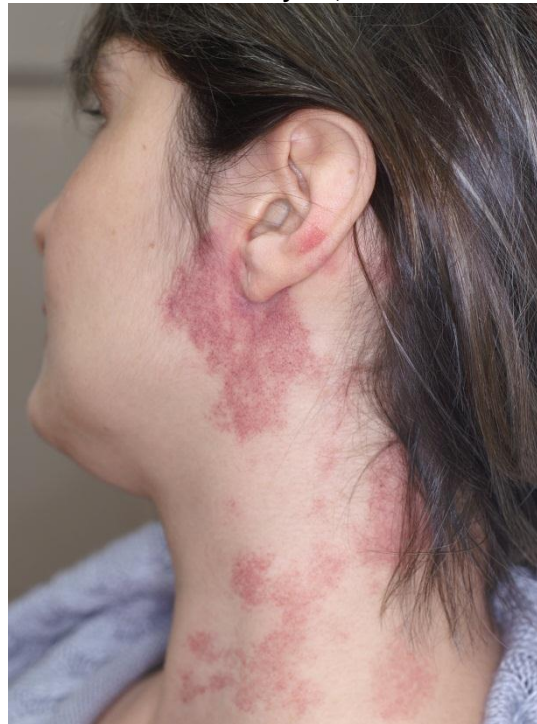Antera Data Chart:



Pre-treatment - February 15, 2011

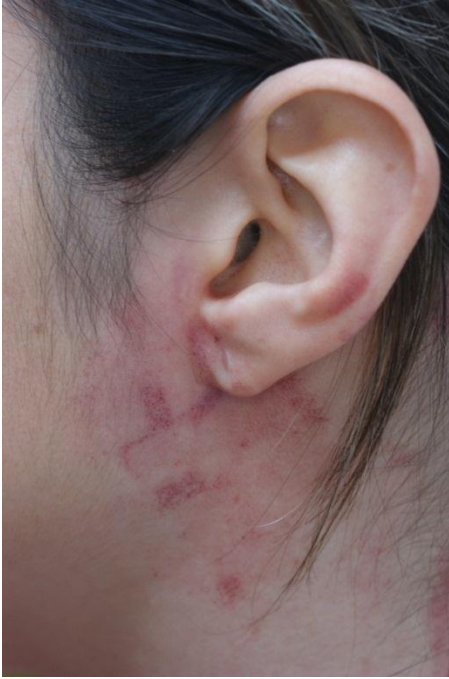

Pre-treatment - February 15, 2011

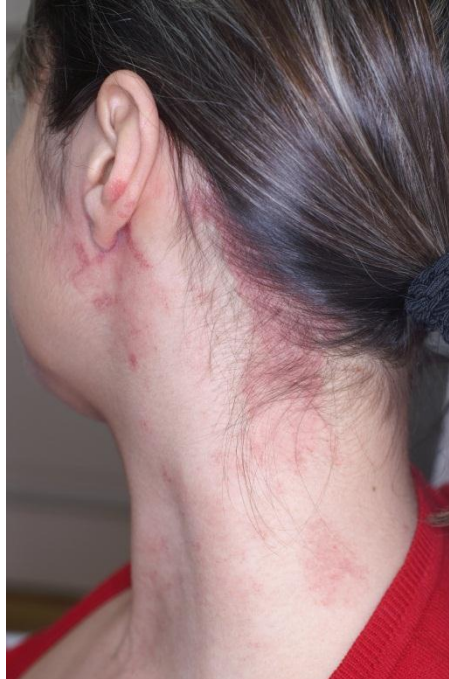

Disclaimer: The opinions expressed herein are those of the author(s), not necessarily those of Palomar Medical Technologies, Inc. ("Palomar"). Palomar and the author(s) assume no liability or responsibility for the contents of this publication. It is provided as a convenience only and is not intended to replace sound judgment or serve as the standard of care. Palomar's suggested guidelines are set forth in the operator's manuals and clinical treatment guides for Palomar products. Ultimately, a practitioner is solely responsible for the care of a particular client in light of all circumstances presented by the client, the diagnostic and treatment options at hand, and the available resources.

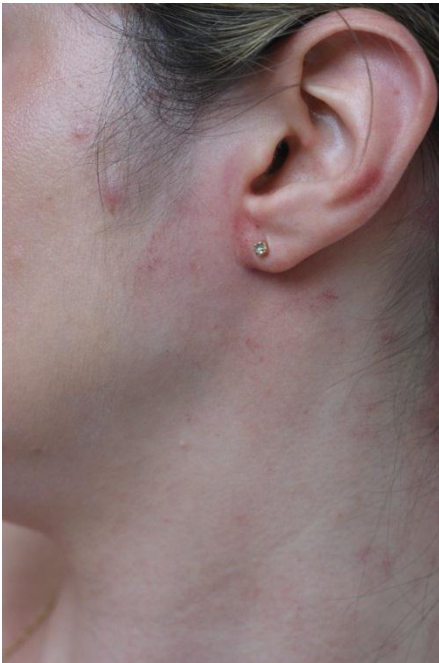March 29, 2011 – 6 Weeks Post 1 Treatment



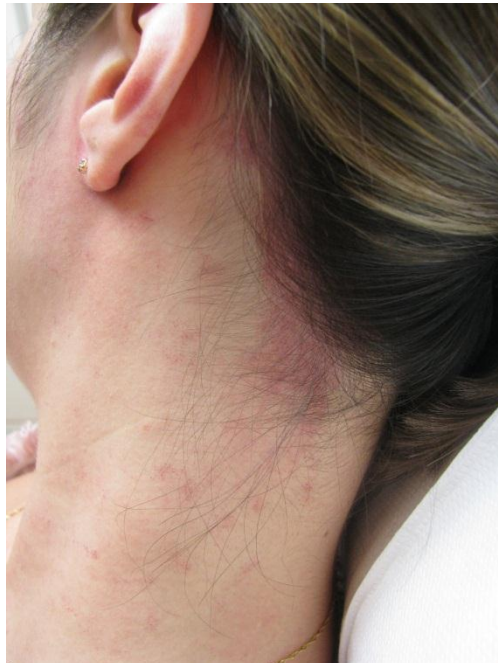March 29, 2011– 6 Weeks Post Treatment 1



May 24, 2011– 6 Weeks Post Treatment 2



May 24, 2011 – 6 Weeks Post Treatment 2



Disclaimer: The opinions expressed herein are those of the author(s), not necessarily those of Palomar Medical Technologies, Inc. ("Palomar"). Palomar and the author(s) assume no liability or responsibility for the contents of this publication. It is provided as a convenience only and is not intended to replace sound judgment or serve as the standard of care. Palomar's suggested guidelines are set forth in the operator's manuals and clinical treatment guides for Palomar products. Ultimately, a practitioner is solely responsible for the care of a particular client in light of all circumstances presented by the client, the diagnostic and treatment options at hand, and the available resources.