


Case Study for Perioral Rhytides using the Lux2940™ and Groove™ Optic

Prepared by: Felicia Whitney R.N.

Date: 11-12-09

Disclaimer: This publication is provided as a convenience only and is not intended to replace sound medical judgment or serve as the standard of medical care. Ultimately, a practitioner is solely responsible for the care of a particular patient in light of all circumstances presented by the patient, the diagnostic and treatment options at hand, and the available resources.

Profile

Case Study for Perioral Rhytides using the Lux2940™ and Groove™ Optic By: Sean Doherty MD	
Physician name	Sean Doherty MD
Address	15 Network Drive
City, state, ZIP Code	Burlington, MA 01803
Phone number	781-418-1310
Fax number	781-993-2330
Web site address	www.palomarmedical.com
MD Photo	

Contact name	Felicia Whitney
Title	Registered Nurse
Phone number	781-993-2300
Fax number	781-993-2330
E-mail address	fwhitney@palomarmedical.com

Disclaimer: This publication is provided as a convenience only and is not intended to replace sound medical judgment or serve as the standard of medical care. Ultimately, a practitioner is solely responsible for the care of a particular patient in light of all circumstances presented by the patient, the diagnostic and treatment options at hand, and the available resources.

Case Study for Perioral Rhytides using the Lux2940™ and Groove™ Optic By: Sean Doherty MD

Introduction:

56 year old female presented desiring treatment for perioral rhytides.

Discussion:

Treatment using the StarLux® 500 system with the Lux2940 Groove™ Optic.

Treatment:

Steps performed:

Face cleansed with chlorhexidine gluconate and isopropyl alcohol impregnated swab.

Anesthetic cream applied to face for one hour prior to treatment.

Anesthetic cream removal with gauze 4x4.

Thorough cleansing with chlorhexidine gluconate and isopropyl alcohol impregnated swab to entire face.

Perioral area treated with Lux2940 Groove™ Optic at 9mj/mB 3ms 7mj/mB (9-3-7). Two passes were completed using the double pulsing method.

Post treatment care was conducted precisely as indicated in Appendix E of the StarLux® 500 Operator's Manual (the latest version of the StarLux Operator's Manual is available in the Product Support area on the [Palomar web site](#).)

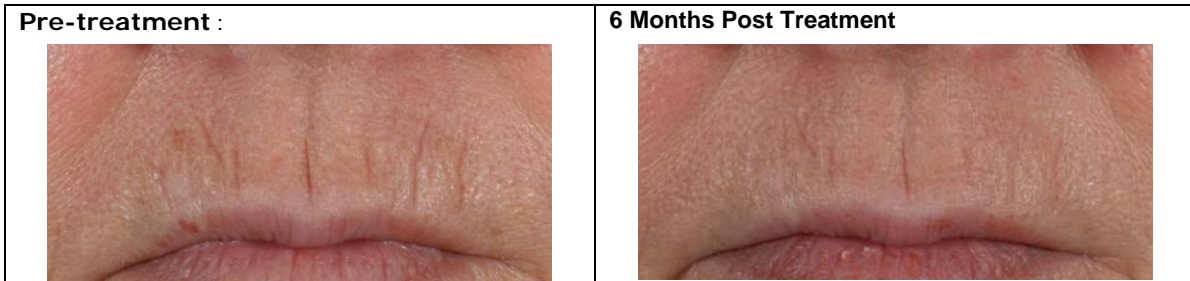Conclusion:

Marked decrease in number and severity of deep rhytides in perioral area.

Physician Quote: "Treating upper lip rhytids is very challenging. Erbium has become a very important tool in the treatments I can offer my patients. The Lux2940 Groove™ Optic provides excellent results. I can achieve improvement of these deep rhytids with minimal to moderate downtime and high patient satisfaction. The ability to perform stacking and multiple passes with the Groove allows me to tailor a Lux2940 treatment very specifically for each patient. I typically offer the upper lip treatment in conjunction with a full face treatment."

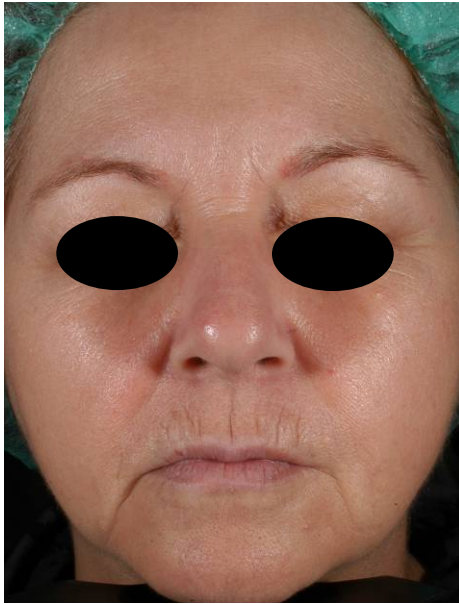Patient Quote: "My upper lip is so smooth and the texture of my skin is much better."

StarLux is a registered trademark and Lux2940 and Groove are trademarks of Palomar Medical Technologies, Inc., Burlington, Massachusetts

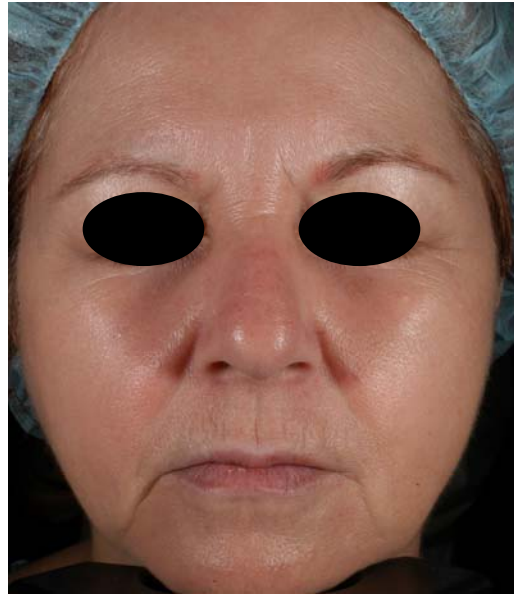

Disclaimer: This publication is provided as a convenience only and is not intended to replace sound medical judgment or serve as the standard of medical care. Ultimately, a practitioner is solely responsible for the care of a particular patient in light of all circumstances presented by the patient, the diagnostic and treatment options at hand, and the available resources.

Pre-treatment :



6 Months Post Treatment



Disclaimer: This publication is provided as a convenience only and is not intended to replace sound medical judgment or serve as the standard of medical care. Ultimately, a practitioner is solely responsible for the care of a particular patient in light of all circumstances presented by the patient, the diagnostic and treatment options at hand, and the available resources.