

White Paper

Treatment of Onychomycosis Using a MicroPulse Nd:YAG Laser: A Case Study

Dr. Daniel Waldman

Blue Ridge Foot Centers, Asheville, NC
Carolinas Toenail Laser Centers, Charlotte, NC

INTRODUCTION

Onychomycosis, a disease caused by dermatophytes, non-dermatophytes and *Candida* species of fungus, is the most common infection of the nail, affecting 2-8% of the general population, and increasing to 12-28% in adults 60 years or older.^{1,2} Nails that are infected with onychomycosis have yellowish or brownish discoloration, a thickened nail plate, and crumbling edges.² These qualities can lead to toenail discomfort, secondary bacterial infections and psychosocial issues such as anxiety, depression, loss of self-esteem, avoidance of intimacy and impaired relationships, all of which can severely affect a patient's quality of life.^{3,4} Several factors, including diminished blood circulation, longer cumulative time of exposure to fungi, nail trauma and a compromised immune system make people more susceptible to infection.⁵ High rates of persistence and recurrence make onychomycosis very difficult to treat.

The primary treatment methods for treating onychomycosis are systemic administration of oral antifungal drugs and topical antifungal creams applied directly to the infected nails.⁶ The most common oral antifungal drugs include Terbinafine, Fluconazole, and Itraconazole.⁶ Long-term cure rates for oral antifungals range from 21% to 53%.⁷ Systemic treatments require liver tests before, during, and after treatment, and can have serious side effects, including diarrhea, dyspepsia, rashes, taste disturbances and abdominal pain.⁶ Patient compliance to the blood testing and requirement to discontinue use of all alcoholic beverages during the course of treatment, can be a challenge. Topical antifungal agents used to treat onychomycosis include nail lacquers containing ciclopiroxolamine, amorolfine, toconazole or a combination of these agents.⁶ Results from several clinical studies indicate that topical cure

rates can range from 21% to 36%.⁸ Factors that make topical antifungals unsuccessful include long-term application (9-12 months), lack of patient compliance, serious side effects and failure to apply the medication appropriately to the nail bed.^{9,10}

Laser therapy has recently become a viable treatment option for onychomycosis. Due to its rapid treatment duration, possibility for efficacy without systemic treatment or blood monitoring, few contraindications and no significant side effects, laser therapy has quickly become a popular treatment option for onychomycosis.¹¹ In addition to these benefits, several studies have demonstrated that laser therapy is both safer and more effective in improving the cosmetic appearance of nails infected with onychomycosis.^{2,3} This case study evaluates the PinPointe™ FootLaser™ as a acceptable and reliable treatment option for onychomycosis.

METHODS

Blue Ridge Foot Centers and Carolinas Laser Toenail Centers have been using the PinPointe laser to treat onychomycosis for over three years. Prior to the laser treatment, if needed, patients receive extensive debridement using nippers, curette and a mechanical filer to remove the distal onycholytic nail plate and thinning of the hypertrophic nail plate to 1mm thickness. A smoke evacuator is used to clear the nail of the debris. Patients are then treated with the micro-pulsed Nd:YAG laser. The laser utilizes the 1064nm wavelength, 200 mJ of energy, a pulse width of 100 µm, spot size of 1.5 mm

and a power setting of 6 watts. Each pulse delivers 10 micropulses over 0.5 seconds and 20 J/cm² with a pulse width of 100 µm. Laser spots were administered in a grid pattern with 1.0-1.5mm spacing. The treating physician holds the handpiece perpendicular to the nail while making two passes of the laser, alternating between transversely and longitudinally. Each pass also includes 2-3mm around the nail. For patients suffering with severe cases of onychomycosis, additional passes may be required.

Patients are provided with a proper post treatment foot care regimen. The anti-fungal medication Clarus[®] (brand name of tolnaftate oil and cream) is applied on and around the toenails daily. The tips, as well as the entire surface of the nail, are filed once a week using a clean emory board and nail trimmers are used by the patient. All tools should be cleaned with rubbing alcohol prior to use. Patients are allowed to use Dr.'s Remedy[®] nail polish but are instructed not to leave it on for more than 3-5 days. Shoes, flip-flops and sandals are disinfected using either Mycomist spray or Sterishoe[®] devices and the bottom of the shower/tub is cleaned using Clorox[®] Clean-Up[®] Spray. Additionally, Biotin supplements at 2.5mg a day, are used to strengthen nails.

CASE REPORT

A 31-year-old Caucasian female, taking no medication, presented with onychomycosis of the big toe. Due to the severity of the infection, the patient received three passes of the PinPointe laser on each toe, using the above parameters. All toes on both feet were treated but only the big toes were used for analysis. The patient returned for follow-up visits at months three, seven and ten.

Photographs were taken at baseline and at follow-up visits to assess lesion reduction and clear nail growth. To achieve consistency with measurements and evaluation of the laser treatment, the following definitions were used:

Clear nail: uniform in color (pink, reddish, flesh or pale) with smooth surface and normal thickness.

Infected nail: abnormal in color (milk white, black, brown, yellow, green) with flakey, distorted, roughened, ridged, or thickened nail plate that may be onycholytic.

Lesion area: total infected area, including discoloration, thickening and yellowing of nail

Lesion area at follow-up: total infected area at follow-up

Clear nail growth: new clear nail that has grown (%) in comparison to the baseline clear nail area

Absolute clear nail: the baseline lesion area (%) minus the follow-up lesion area (%)

Lesion reduction: the absolute lesion decrease % divided by the baseline lesion area (%)

Image analysis with Adobe Photoshop was used to achieve consistent magnification of the nails. A trained technician traced the area of clear and infected nail for an accurate evaluation of nail improvement. Photos were neither enhanced nor filtered, hence the margin between clear and infected nail was unaffected.

Magnified photos were then analyzed using ImageJ software, a National Institutes of Health (NIH) based program designed specifically for image analysis and processing. The software program converts images into their individual pixels so that different areas within the image can be analyzed. To calculate the size of the area, clear nail area or the infected nail area was selected and converted into pixels. These measurements were then used to analyze the changes in clear nail area and lesion reduction at follow-up visits. Standard deviation was calculated to determine the variation that existed from the average.

Subjective aesthetic assessments were measured by the physician using the Global Aesthetic Improvement Scale (GAIS). GAIS is a 5-point scale to evaluate the treatment outcome of the infected area. Subjects filled in a patient satisfaction questionnaire during follow-up visits at three and seven months.

GAIS Evaluation

5	Very much improved – optimal cosmetic results
4	Much improved – marked improvement in appearance from initial condition, but not completely optimal for this subject
3	Improved – obvious improvement in appearance from initial appearance, but a retreatment is indicated
2	No change - the appearance is essentially the same as the original condition
1	Worse – the appearance is worse than the original condition

RESULTS

The patient's two big toes were measured by planimetry and showed a significant increase in clear nail growth and lesion reduction (Figure 1,2). The mean baseline clear nail area for the patient's two toes was 17% (±32%) of the nail. After 14 months posttreatment, the mean clear nail area was increased to 49% (±5%) of the nail. Using these two measurements, the absolute increase in clear nail was calculated to be 32%. (Table 1).

Clear Nail Growth Determined by Area Calculated in ImageJ (cm²)

Follow-Up Period	# of Toes	Mean Baseline Clear Nail Area	Std. Dev.	Mean Follow-up Clear Nail Area	Std. Dev.	Absolute Increase in Clear Nail
14 Months	2	17%	11%	49%	5%	32%

Table 1 Improvement as quantified by increase in clear nail

The mean lesion area of the patient's two big toes was determined to be 83% ($\pm 11\%$) of the nail and was reduced to 51% ($\pm 5\%$) of the nail at 14 months follow up. Based on the mean baseline lesion area and the mean follow up lesion area, absolute lesion reduction was calculated to be 32% and lesion reduction vs. baseline was calculated to be 75%. (Table 2). The physician rated the patient's clinical outcome a 4 on the Global Aesthetic Improvement Scale (GAIS).

Lesion Reduction Determined by Area Calculated in ImageJ (cm²)

Follow-Up Period	# of Toes	Mean Baseline Lesion Area	Std. Dev.	Mean Follow-up Lesion Area	Std. Dev.	Absolute Lesion Reduction	Lesion Reduction (% Baseline)
14 Months	2	83%	11%	51%	5%	32%	75%

Table 2. Improvement as quantified as the lesion area reduction (% of baseline)

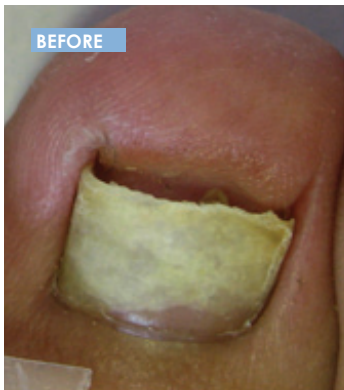

Figure 1. Patient's left foot

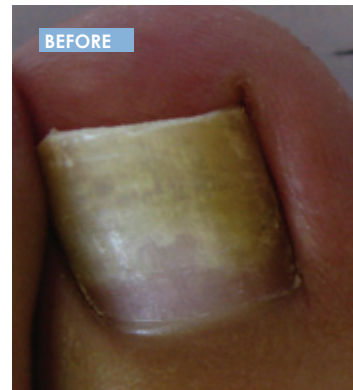
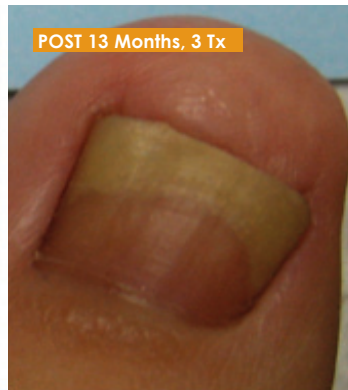

Figure 2. Patient's right foot

DISCUSSION

In our experience, treatment with the PinPointe laser not only allows for significant growth of clear nail in toes infected with onychomycosis, but the laser treatment also produces high patient satisfaction. In this case study, the efficacy of the micropulsed 1064nm Nd:YAG laser was evaluated based on clear nail growth and reduced lesion area. The patient experienced a significant improvement in both areas. The clear nail area of the patient increased from 17% of the nail to 49% of the nail, and there was a 75% reduction in lesion area. In addition to the significant efficacy of the PinPointe laser treatment as demonstrated by planimetry measurements, the physician also noticed a significant improvement in the nail. Using the Global Aesthetic Improvement Scale,

the physician rated the patient's improvement as a 4, indicating that the nails were much improved and there was marked improvement in appearance from the initial condition. The results of this case study suggest that the PinPointe FootLaser is an effective treatment option for onychomycosis.

CONCLUSION

The PinPointe laser is an effective treatment option that produces high patient and physician satisfaction. Laser treatment allows for clear nail growth without the significant side effects and complications that come with other treatment modalities.

REFERENCES

- 1 Finch J, and Warshaw E, "Toenail Onychomycosis: Current and Future Treatment Options," *Journal of Dermatologic Therapy*, 2007; 20:31-46.
- 2 Hochman LG, "Laser Treatment of Onychomycosis Using a Novel 0.65-millisecond Pulsed Nd:YAG 1064-nm Laser," *Journal of Cosmetic and Laser Therapy*, 2011; 13:2-5.
- 3 Menevitch Z, Lev D, Hochberg, Palhan M, Lewis A, and Enk CD, "Direct Antifungal Effect of Femtosecond Laser on Trichophyton Rubrum Onychomycosis," *Photochemistry and Photobiology*, 2010; 86: 476-479.
- 4 Finch, JJ, and Warshaw EM, "Toenail Onychomycosis: Current and Future Treatment Options," *Dermatologic Therapy*, 2007; 20: 31-46.
- 5 Nasir A, Goldstein B, van Cleff, M, and Swick L. "Clinical Evaluation of Safety and Efficacy of a New Topical Treatment for Onychomycosis", *Journal of Drugs in Dermatology*, October 2011; 10(10): 1186-1191.
- 6 Welsh O, Vera-Cabrera L, and Welsh E, "Onychomycosis," *Clinics in Dermatology* 2010; 28: 151-159.
- 7 Sigurgeirsson, B, Olafsson, JH, Steinsson, JB, Paul, C, Billstein, S and Evans, EG, "Long-Term Effectiveness of Treatment with Terbinafine vs. Itraconazole in Onychomycosis: A 5-Year Blinded Prospective Follow-Up Study," *Archives of Dermatology*, 2002; 138, 353-357.
- 8 Gupta AK, Schouten JR, and Lynch LE, "Ciclopirox Nail Lacquer 8% for the Treatment of Onychomycosis: A Canadian Perspective," *Skin Therapy Letter*, 2005; 10:1-3.
- 9 Leshner JL Jr., "Oral Therapy of Common Superficial Fungal Infections of the Skin," *Journal of the American Academy of Dermatology*, 1999; 40 (6 pt 2): S31-S34.
- 10 Koehler AM, and Maibach HI, "Electronic Monitoring in Medication Adherence Measurement: Implications for Dermatology," *American Journal of Clinical Dermatology*, 2001; 2:7-12.
- 11 Piraccini BM, Rech G, and Tosti A, "Photodynamic Therapy of Onychomycosis Caused by Trichophyton Rubrum," *Journal of the American Academy of Dermatology*, 2008; 59 (% Supplement): S75-76.
- 12 National Institutes of Health



www.cynosure.com